

Assessment of intraoperative neurosurgical planning with the Microsoft HoloLens

Zachary Baum¹, S. Ryan¹, E. Rae¹, A. Lasso¹, T. Ungi^{1,2}, R. Levy², G. Fichtinger^{1,2}

1. Laboratory for Percutaneous Surgery, Queen's University, Kingston, Canada
2. Department of Surgery, Queen's University School of Medicine, Kingston, Canada

INTRODUCTION: Neurosurgical lesions are inherently difficult to visualize due to their potentially complex shapes, which can be hidden within the skull or spinal canal [1]. Augmented reality (AR) is a technology in which computer-generated images are blended with a user's view of the real world. This technology enables the wearer to look 'inside' patients in 3D, in real time. We seek to assess whether the use of AR can aid in denoting surgical targets through an intraoperative performance comparison.

METHODS: An Institutional Research Ethics Board approved prospective cohort study was performed. Enrollment and consent were obtained from each patient subject, trainee (medical student, surgery resident), and neurosurgeon participant.

A surgical planning system was developed using the Microsoft HoloLens. Patient subject computerized tomography or magnetic resonance imaging was used to create 3D models of the patient's skin surface, brain, and intra-cortical lesion. Patient models are loaded to our system and brought into the operating room where participants must denote a surgical access point and trajectory with a conventional "anatomical" method and with our AR system. The conventional method allows use of only the patient's pre-operative images for reference to complete the task. Our AR method allows use of our system to view holographic models of the anatomy 'inside' the patient to complete the task (Fig. 1).

The denoted surgical access point and trajectory was compared to the gold-standard defined using a commercial surgical navigation system. The comparison was based on distance between participant access point and gold-standard access point (distance to access point), distance between participant trajectory and the lesion's center (distance to lesion), angle between participant trajectory and gold-standard trajectory (angle to access point), and angle between participant trajectory and trajectory between participant access point and the lesion's center (angle to lesion) (Fig. 2). Results are presented as mean [minimum-maximum].

RESULTS: Fifteen intraoperative assessments were completed. A one-tailed Mann-Whitney U Test for independent unpaired samples demonstrated significant reductions in distance to access point (33 [13-68] vs. 21 [2-44] mm, $p=0.031$), distance to lesion (19 [5-49] vs. 13 [1-43] mm, $p=0.037$), and angle to lesion (29 [4-67] vs. 17 [1-53] deg., $p=0.015$) for trainees (n=15) using the AR system compared to the conventional approach. While mean angle to access point also decreased (37 [9-84] vs. 29 [11-57] deg., $p=0.44$) for trainees, the decrease was not significant. Neurosurgeon (n=15) mean distance to access point (13 [5-28] vs. 10 [4-21] mm, $p=0.18$) and mean distance to lesion (11 [4-20] vs. 10 [3-20] mm, $p=0.17$) were not significantly lower using the AR system. Mean angle to access point (18 [3-28] vs. 18 [2-35] deg.) and mean angle to lesion (13 [5-27] vs. 13 [3-36] deg.) had no decrease.

CONCLUSION: A surgical planning system was developed using the Microsoft HoloLens to assess use of AR for denoting surgical targets intraoperatively. Overall, mean trainee performance was improved by the AR system, and neurosurgeon performance was largely unaffected by the AR system.

REFERENCES: [1] Meola *et al.*, *Neurosurgical Review*, 2017.

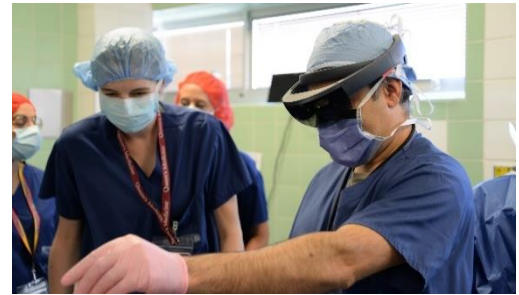

Figure 1. Neurosurgeon using the HoloLens to denote the surgical access point and trajectory.

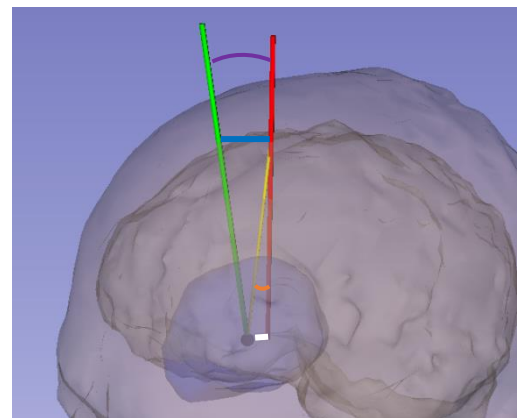


Figure 2. 3D models of surface anatomy, brain, and lesion from one case in our study.

Black point shows lesion center of mass; *green line* shows gold-standard access point and trajectory; *red line* shows participant access point and trajectory; *yellow line* shows trajectory from participant access point to lesion's center; *blue line* shows distance to access point; *white line* shows distance to lesion; *purple arc* shows angle to access point; *orange arc* shows angle to lesion.