

mindcull.com (beta)

A searchable database of scientific abstracts.

All the knowledge in the world is useless unless you know where to find it. ©2008, mindcull.com

Full Description



American Urological Association 99th Annual Meeting May 8 - 13, 2004, San Francisco, California

TECHNIQUE AND ACCURACY OF A CLINICAL SYSTEM FOR TRANSRECTAL INTRAPROSTATIC NEEDLE PLACEMENT IN A STANDARD 1.5T MRI SCANNER

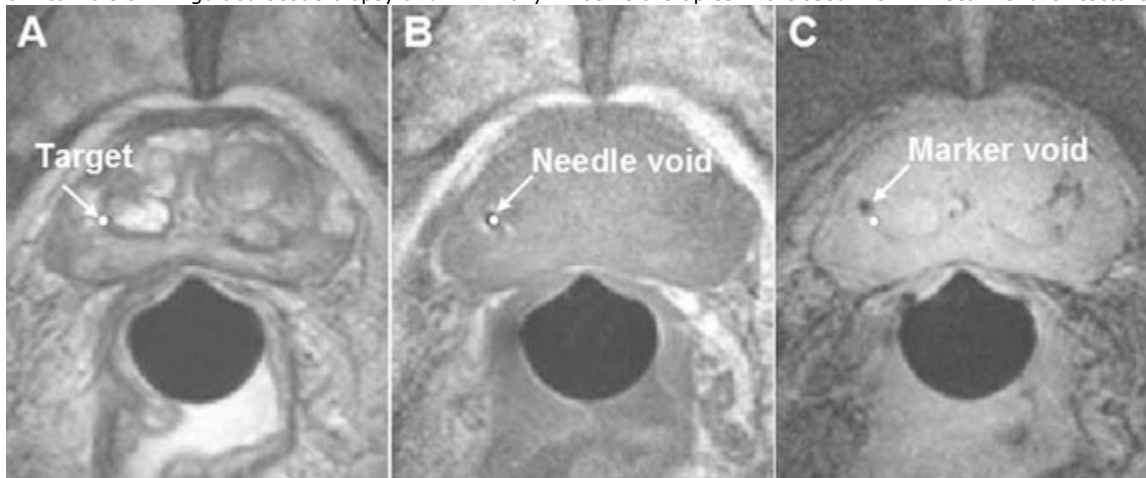
Robert C Susil*, Baltimore, MD; Jonathan A Coleman, Bethesda, MD; Axel Krieger, Baltimore, MD; Kevin Camphausen, C Norman Coleman, W Marston Linehan, Bethesda, MD; Gabor Fichtinger, Louis L Whitcomb, Ergin Atalar, Baltimore, MD; Cynthia Mnard, Bethesda, MD.


INTRODUCTION AND OBJECTIVE: The purpose of this study was to investigate the safety and accuracy of a system that provides transrectal needle access to the prostate during imaging in a standard 1.5T MR scanner. Because the system is used within a "closed-bore" scanner, it can capitalize on the higher signal provided by traditional magnet designs, which is crucial for accurate tumor localization.

METHODS: Using a custom designed system (Figure 1) and a GE Signa Excite 1.5T MR scanner, four gold fiducial markers were placed within the prostate gland in each of four patients with localized prostate cancer. By depositing fiducial markers within the gland, we were able to assess not only needle placement accuracy, but also of the accuracy with which the tissue itself was targeted (i.e. leaving a permanent marker allows for measurement of the impact of tissue deformation, produced during needle insertion, on targeting accuracy).(Figure1)

RESULTS: The mean MR procedure duration was 72 minutes; all patients tolerated the intervention well and no CTC grade II or higher urinary complications were reported. Using axial MR images (Figure 2), needle and marker placement errors were assessed. Mean needle placement accuracy was 1.9 mm and mean fiducial marker placement error was 4.8 mm. The mean fiducial marker placement error transverse to the needle direction (the most relevant predictor of accuracy in collecting core biopsies) was 2.6 mm. The gold fiducial markers were subsequently used to assess daily setup errors and off-line organ motion during a standard course of external beam radiation therapy for prostate cancer.(Figure2)

CONCLUSIONS: Having established the accuracy, safety, and feasibility of this 'APT-MRI' system (Access to Prostate Tissue under MRI-guidance), further studies involving larger patient cohorts are warranted to investigate the potential clinical role of MR-guided tissue biopsy and minimally-invasive therapies in a closed 1.5T MR scanner architecture.





Discussed Poster - Wednesday, May 12, 2004, 8:00 AM - 12:00 PM