

Localization of the transverse processes in ultrasound for spinal curvature measurement

Shahrokh Kamali^{1,2}, Tamas Ungi¹, Andras Lasso¹, Christina Yan¹, Matthew Lougheed¹, Gabor Fichtinger¹

¹Laboratory for Percutaneous Surgery, Queen's University, Kingston, ON, Canada

²Electrical and Computer Engineering Department, Dalhousie University, Halifax, NS, Canada

ABSTRACT

PURPOSE: In scoliosis monitoring, tracked ultrasound has been explored as a safer imaging alternative to traditional radiography. The use of ultrasound in spinal curvature measurement requires identification of vertebral landmarks such as transverse processes, but as bones have reduced visibility in ultrasound imaging, skeletal landmarks are typically segmented manually, which is an exceedingly laborious and long process. We propose an automatic algorithm to segment and localize the surface of bony areas in the transverse process for scoliosis in ultrasound.

METHODS: The algorithm uses cascade of filters to remove low intensity pixels, smooth the image and detect bony edges. By applying first differentiation, candidate bony areas are classified. The average intensity under each area has a correlation with the possibility of a shadow, and areas with strong shadow are kept for bone segmentation. The segmented images are used to reconstruct a 3-D volume to represent the whole spinal structure around the transverse processes. **RESULTS:** A comparison between the manual ground truth segmentation and the automatic algorithm in 50 images showed 0.17 mm average difference. The time to process all 1,938 images was about 37 Sec. (0.0191 Sec. / Image), including reading the original sequence file.

CONCLUSION: Initial experiments showed the algorithm to be sufficiently accurate and fast for segmentation transverse processes in ultrasound for spinal curvature measurement. An extensive evaluation of the method is currently underway on images from a larger patient cohort and using multiple observers in producing ground truth segmentation.

Keywords: ultrasound automatic bone segmentation, transverse process localization, scoliosis

1. INTRODUCTION

Currently the most popular imaging modalities used to view skeletal structures within the human body is X-ray imaging, owing to its superior clarity and contrast in showing bones. Scoliosis, an abnormal lateral curvature of the spinal, occurs in approximately 1-2% of adolescents, and 10-20% of these patients require therapy due to progression of their disease [2]. Progression in spinal curvature is monitored with X-rays taken every 3-6 months, beginning from diagnosis through full development of the spine. However, cumulative radiation exposure is a concern prevalent in screening pediatric patients, because it increases the risk of breast cancer, leukemia and prostate cancer [1]. Ultrasound (US) imaging is a promising alternative; it is safe, low-cost, portable and real-time, but small field of view and low image quality are currently limit its usefulness in spinal imaging. Electromagnetically tracked US allows for piecewise imaging of the entire spine and it has been proposed for scoliosis measurement [3]. Current methods of the spinal curvature measurement by US involve manual localization of the centers of transverse processes [3] or the centers of lamina [4] as landmarks. These landmarks are used to identify the vertebral rotation at each level in US images to measure the spinal curvature. An US sequence targeted at the landmarks contains hundreds of images and a non-targeted sweep of the spine may contain several thousands. Manual inspection and segmentation of such a large number of images is impossible in a

practical clinical setup. To address this issue, we developed an automatic algorithm for segmentation of bony surface of the transverse process in US images for scoliosis measurement.

2. METHODS

Our generic approach using tracked ultrasound imaging (Figure 1) involves three steps: read the sequence of tracked US images, segment the surface of the transverse processes in each 2-D image (Figure 2, left), and reconstructs a 3-D volume of the bony areas around the transverse processes from the segmented images (Figure 2, middle and right).

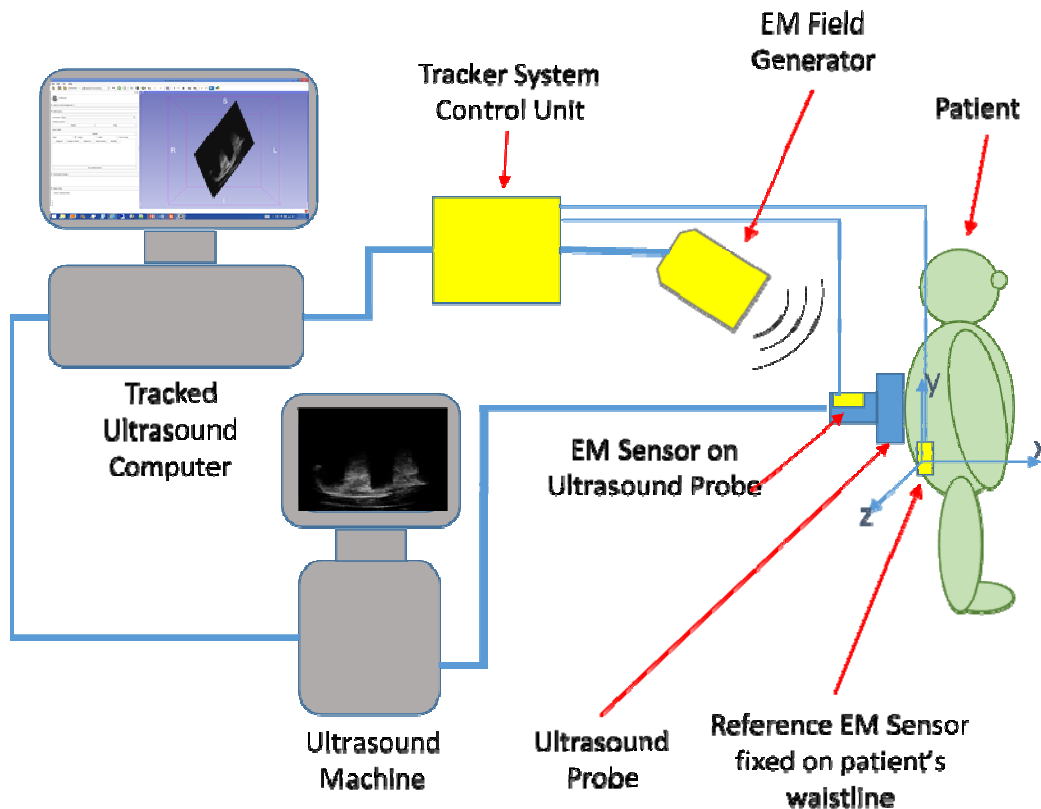


Figure 1. Tracker system unit uses EM field and EM sensors to identify the real-time spatial location of US probe in 3-D space with a coordinate system at reference EM sensor.

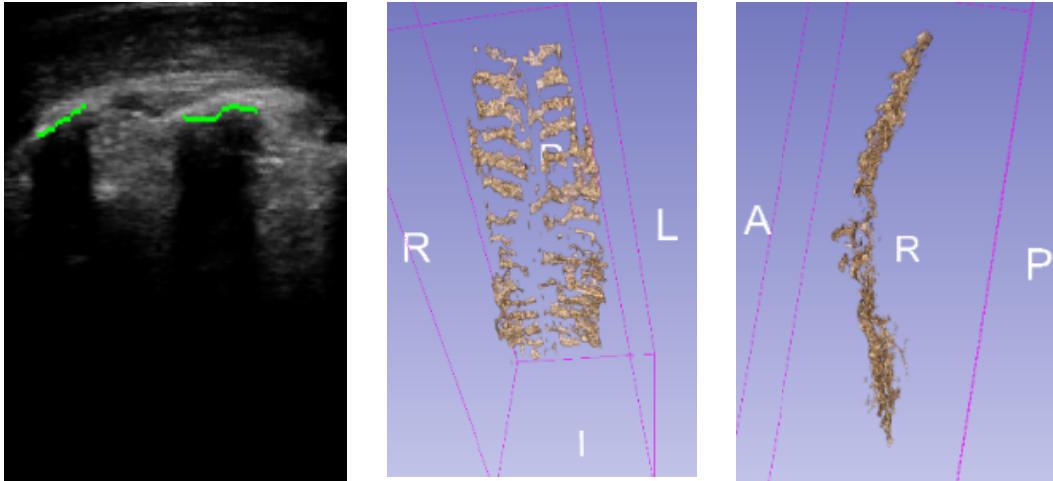


Figure 2. Example of automatic 2-D bone segmentation in a tracked US image (left), coronal view of reconstructed 3-D volume (middle), and sagittal view of reconstructed 3-D volume (right)

SonixTouch (Analogic Corp., Peabody, MA, USA) US machine was used to capture 2-D spinal structure images. An integrated 3D trakSTAR (NDI, Waterloo, ON, Canada) electromagnetic tracker was used to generate spatial data to reconstruct 3-D volume from tracked 2-D US images and localize the transverse process surface. An electromagnetic position sensor was attached to the patient's lower back as a reference for coordinating purpose to indicate anatomical orientation. A curvilinear US transducer was equipped with internal electromagnetic positioning sensor. The US was working at frequency of 2.5 MHz and imaging depth of 100 mm. The PLUS software (www.plustoolkit.org) was used to synchronize and calibrate US image tracking. The images were sent the open source 3D Slicer (www.slicer.org) and its SlicerIGT extension (www.slicerigt.org), saved, replayed and analyzed as a sequence file. MATLAB 2015a was used to implement the proposed automatic 2-D bone segmentation algorithm to localize the surface of transverse process in each individual 2-D image.

The following major steps comprise the proposed segmentation algorithm:

- 1- Read .mha sequence file in MATLAB (Curvilinear images need to be processed and scan lines extracted to make them linear before processing) and filter low intensity pixels
- 2- Smooth the image by a Gaussian filter and Apply Sobel Edge detector filter
- 3- Keep the high intensity edges far from probe, save it as a signal and filter the rest edges
- 4- Apply first differentiation to the front edges signal to locate the start and end of each high possibility bony area
- 5- A high intensity area is not bone, if there is no shadow. For instance, area B in Figure 3 has a shadow if the average intensity in the B area is less than average intensity in A and C areas. Following formula used to calculate average intensity in B area:

$$\sum_{row=1}^R \sum_{col=i}^{i+L/2} Intensity(row, col)$$

$$\text{Average intensity in B} = \frac{\quad}{(R2-R1)*L/2}$$

- 6- Create an inspection window around each reminded areas to search for bony edges with higher accuracy
- 7- Search for high intensity pixels, edges and apply some morphological operation to segment the bony area
- 8- Save the segmented bony areas in a sequence file

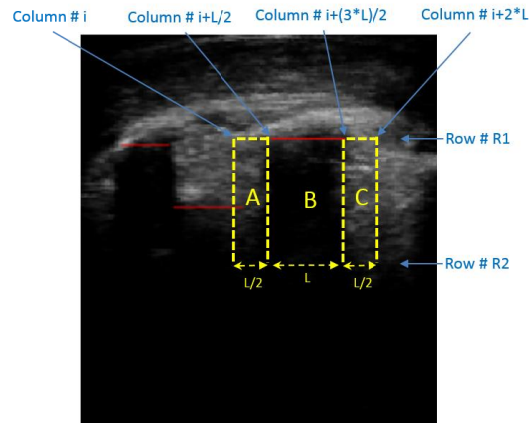


Figure 3. B area has shadow if the average intensity in the B area is less than average intensity in A and C areas

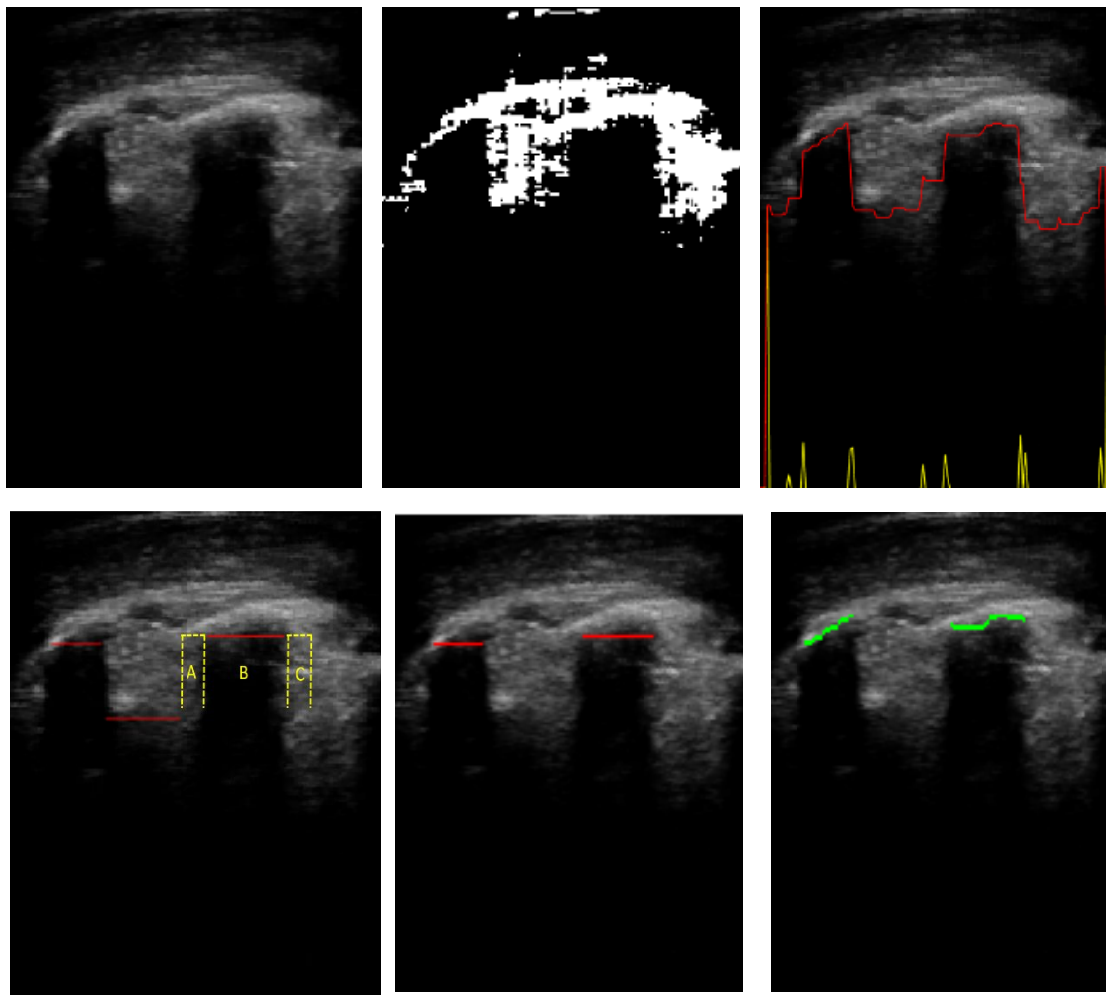


Figure 4. Original image (top left), Pixels with intensity $> \text{Maximum intensity} - 3 \times \text{standard deviation}$ (top middle), Red and yellow signals represent front edge of possible bony area and the first derivative respectively (top right), Shadow in B area (bottom left), Areas with shadow (bottom middle), Segmented bony area (bottom right)

3. RESULTS

The surface of bony areas were automatically segmented and 3-D volumes were reconstructed to visualize transverse processes in 12 US sequence files. To evaluate the accuracy of the automatic segmentation, we compared manual segmentation and automatic segmentation to localize the centre of segmented bony area in 50 US images. The average difference was 2.16 pixel (0.17 mm). The usage time to process 1938 images is about 37 Sec. (0.0191 sec/image), including reading the original sequence file. Figure 5 shows an example, where the difference between automated and manual segmentation is 2 pixels (0.16 mm). Figure 5 and Figure 6 show the centre of bony area and difference in mm and pixel for 50 images.

We have observed that the sonographer's skills has a key role to obtain images with strong shadow under high intensity bony areas. In some cases, we found that the US scan did not contain enough information from some areas of the spine, typically of the lumbar spine. This suggests that the US scanning protocol must include more thorough validity check before the patient is released. Our automatic algorithm is fast enough to provide a feedback by real-time segmentation of each image and thus it could be included in the scanning protocol to display segmented images in real-time, allowing the sonographer to take immediate action to reposition the probe over the target structure or to adjust movement speed, probe angle or pressure while scanning the patient. We are implementing a new algorithm to display real-time feedback to sonographer (Figure 7).

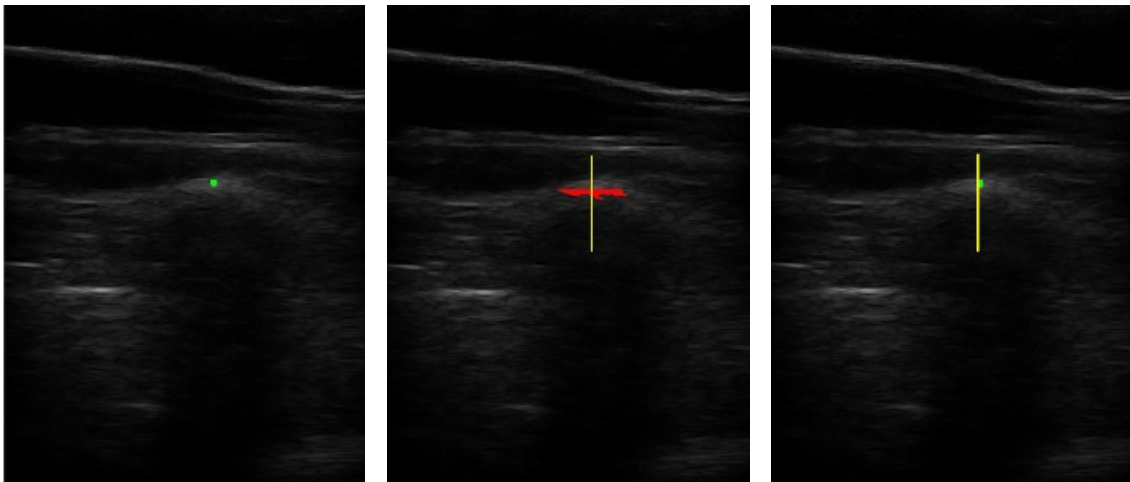


Figure 5. Example: manually landmarked (left), automatically segmented and the centre line (middle), the difference between manually landmarked and automatic segmentation to localize the centre of bony area is 2 pixels or 0.16 mm (right)

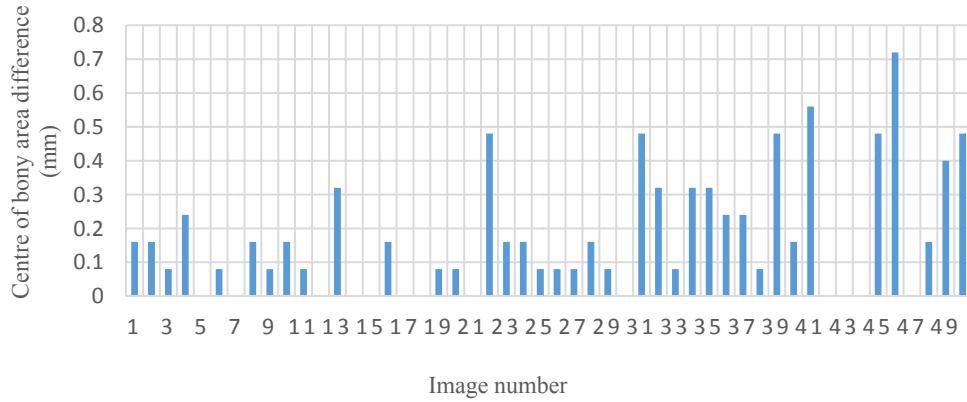


Figure 6. Difference between manual landmarked and automatic segmentation to localize the centre of bony area

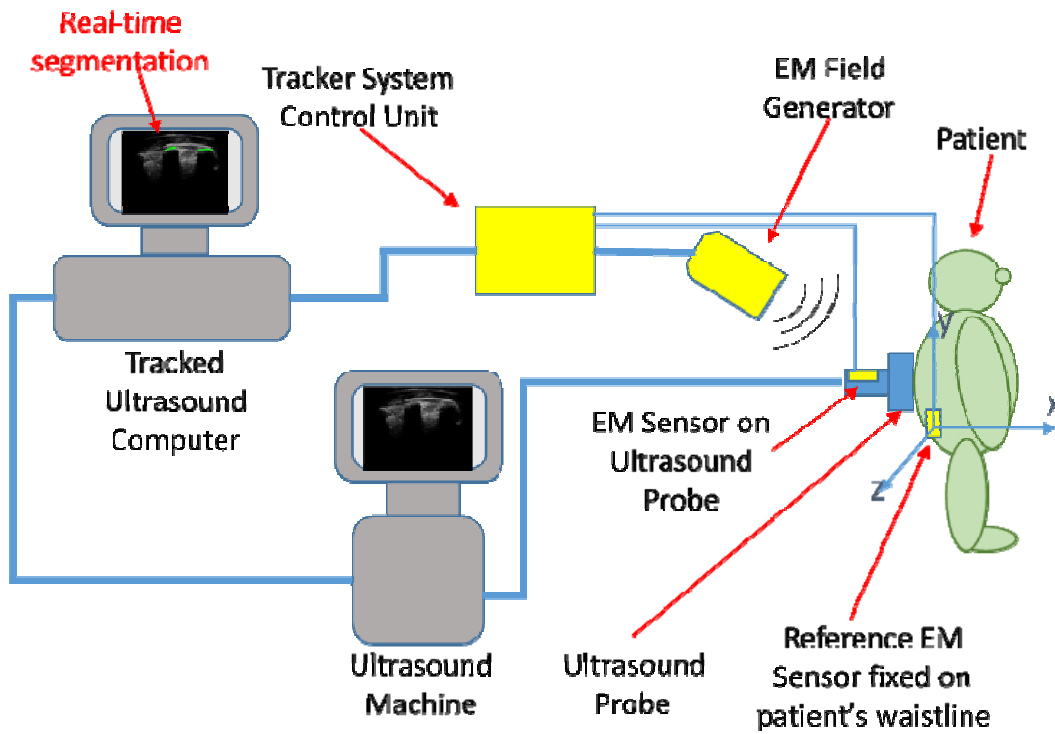


Figure 7. Real-time segmentation feedback to sonographer

4. DISCUSSION

We present an automatic transverse process segmentation method that demonstrates sufficient accuracy and speed to localize the centre of transverse processes for spinal curvature measurement in a clinical setup without ionizing radiation exposure. Our method could be used in scoliosis monitoring and spinal curvature measurement, by identification of

vertebral landmarks such as transverse processes. Two landmark points in each vertebra define both the scoliosis and rotation angles of the vertebra, which are critical measurements in making decisions on therapeutic options of these patients.

For further proof of usability, we need to process and test more samples collected from different ultrasound machines and sonographers. Ultrasound image quality largely depends on the sonographer's skills, therefore, having a strong scanning protocol and real-time segmentation feedback to sonographer are part of our future goals to improve automatic transverse process segmentation algorithm. With the real-time feedback, the sonographer will be able to go back to areas where the angle of the ultrasound or the contact with the patient was not ideal.

An US sequence file contains hundreds to several thousands of images. Current manual or semiautomatic methods for localization of the centers of transverse processes by US are time consuming and are not practical in clinical setups. Our algorithm is automatic and real-time, so it is fast and ideal for scoliosis measurement and monitoring, when the operator needs enhanced bone signal for selecting anatomical landmarks.

5. CONCLUSION

The automatic transverse process segmentation could visualize the transverse processes in scoliotic spinal anatomy with acceptable accuracy and speed. This algorithm may be extended to localize other bony structures such as knee, finger and elbow and perhaps also in fracture detection and monitoring. We conclude that our algorithm is a promising method in scoliosis monitoring. By testing our method on more US images and obtaining further proof of reusability, it could be a modality with advantages of safety, portability and low cost over radiography.

ACKNOWLEDGEMENTS

I am thankful to my supervisor Dr. Joshua Leon at Dalhousie University, who supported my PhD program and also grateful to Laboratory for Percutaneous Surgery at Queen's University that allowed me to work as a Visiting Research Student.

REFERENCES

- [1] Hoffman DA, Lonstein JE, Morin MM, Visscher W, Harris BS 3rd, Boice JD Jr., "Breast cancer in women with scoliosis exposed to multiple diagnostic x rays," *J Natl Cancer Inst* 81 (17):1307-1312 (1989).
- [2] Reamy BV, Slakey JB., "Adolescent idiopathic scoliosis: review and current concepts," *Am Fam Physician.*; 6 4 (1):111- 116 (2001).
- [3] Ungi T, King F, Kempston M, Keri Z, Lasso A, Mousavi P, Rudan J, Borschneck DP, Fichtinger G., "Spinal curvature measurement by tracked ultrasound snapshots," *Ultrasound in Med. & Biol.*, Vol. 40, No. 2, pp. 447-454, 2014.
- [4] Wang Q, Li M, Lou EHM, Wong MS., "Reliability and Validity Study of Clinical Ultrasound Imaging on Lateral Curvature of Adolescent Idiopathic Scoliosis," Williams BO, ed. *PLoS ONE*. 10(8): e0135264. doi: 10.1371/journal.pone.0135264 (2015).