

Design and Preliminary Clinical Studies of an MRI-Guided Transrectal Prostate Intervention System

Axel Krieger¹, Peter Guion², Csaba Csoma¹, Iulian Iordachita¹, Anurag K. Singh^{2,3}, Aradhana Kaushal², Gabor Fichtinger^{1,4}, Louis L. Whitcomb¹

¹The Johns Hopkins University, Baltimore, Maryland

²NCI - NIH-DHHS, Bethesda, Maryland

³Roswell Park Cancer Institute, Buffalo

⁴Queen's University, Kingston, Ontario

Topic: Robotics

Presentation: Oral

Presenting Author: Axel Krieger, Ph.D. Candidate
Laboratory for Computational Sensing and Robotics
Department of Mechanical Engineering
CSEB 112
Johns Hopkins University
3400 North Charles Street
Baltimore, MD 21218-2682
Phone : (410) 516-8021
Fax : (410) 516-4316
E-mail: axel@jhu.edu
WWW: <http://robotics.me.jhu.edu/~axel/>

1 Introduction and Objective

This paper reports on the development and preliminary clinical studies of a new system for MRI guided transrectal prostate interventions. This system employs a novel hybrid tracking method which (a) reduces procedure time and (b) simplifies deployment on different scanners while achieving the needle placement accuracy of more complex previously reported methods, e.g. [1,2]. Transrectal MRI guided prostate interventions such as biopsies and gold marker placements inside a high-field MR scanner have been reported in initial clinical trials, utilizing active [1,2] and passive fiducial tracking [3]. MRI provides superior soft-tissue contrast and has the potential to improve image-guided prostate interventions presently performed with ultrasound [4].

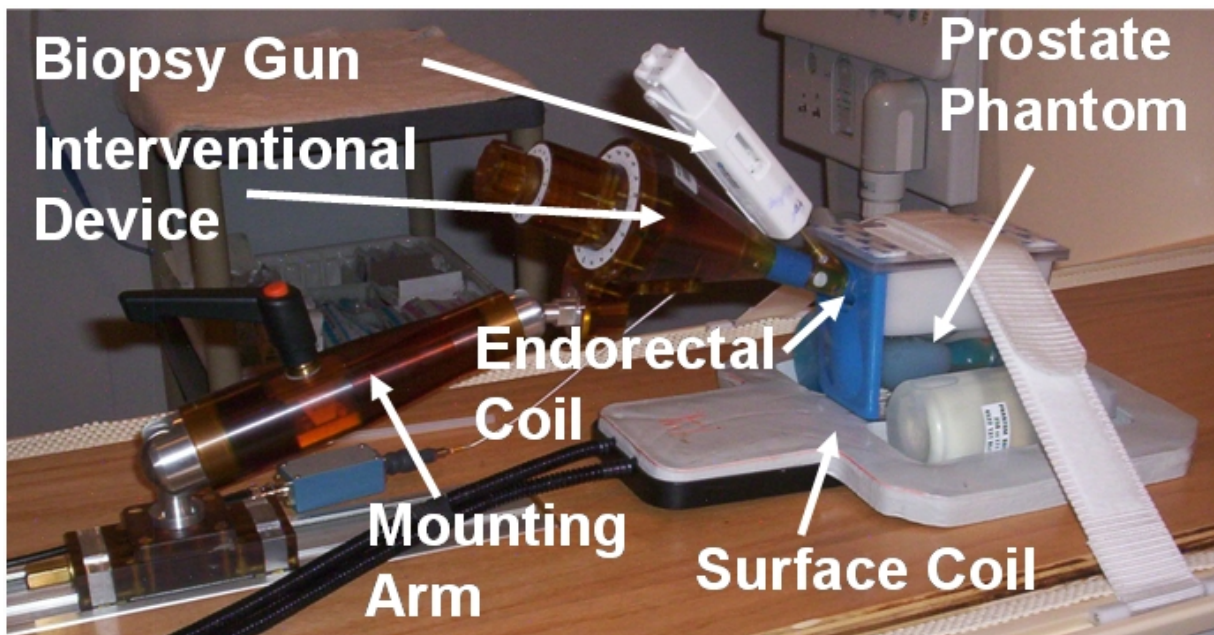


Figure 1: MRI-guided transrectal imaging and biopsy device with integral endorectal imaging coil placed in a prostate phantom.

2 Materials and Methods

Figure 1 shows the interventional device placed in a standard prostate phantom (CIRS Inc, Norfolk, VA). The device guides the needle tip of a standard automatic MR compatible biopsy gun (Invivo Germany GmbH, Schwerin, Germany) to a predetermined target in the prostate. The device contains an endorectal probe with integrated single loop imaging coil. A two channel surface imaging coil is placed underneath the phantom to enhance the MRI signal. A steerable needle channel is integrated into the probe. The three degrees of freedom (DOF) to reach a target in the prostate are rotation of the probe, angulation change of the steerable needle channel, and insertion of the needle.

The interventional device incorporates a hybrid tracking method comprised of passive fiducial marker tracking and joint encoders. At the beginning of the procedure, the initial position of the interventional device is obtained from MR images by segmenting fiducial markers placed on the

device (Figure 2). Motion along the degrees of freedom of the interventional device from the initial position, is redundantly encoded by mechanical scales and MR compatible fiber optic joint encoders.

The interventional device employs two gadolinium fiducial marker tubes (Beekley Corp., Bristol, CT) incorporated into the main axis of the device and two marker tubes placed in line with the needle channel. A thin slab of 1x1x1mm isotropic, sagittal, proton density (PD) weighted TSE images in the plane of the markers is obtained. The software reformats the sagittal images as axial images along the main axis of the interventional device and along the needle axis. In these reformatted axial images the tubular markers appear as circles, allowing for precise automatic segmentation of the fiducial marks (Figure 3). The automatic segmentation is robust to images containing air bubbles in the marker (Figure 3). The position of the two axes can then be calculated, thus defining the initial position of the interventional device.

Rotation and needle angle are encoded separately by (a) mechanical scales and (b) custom MRI compatible quadrature fiber-optic encoders with an angular resolution of 0.25 degrees. Clinical studies have presently not been performed with the fiber optic encoders. Insertion of the needle is accomplished manually by using the scale on the needle to determine depth. The targeting software provides the necessary rotation, needle angle, and needle depth for a given target.




Figure 2: Typical axial image slices of a passive fiducial marker employed in the experimental evaluation. A thin slab of isotropic 1 x 1 x 1mm oblique sagittal PD-weighted TSE images were obtained along the axis of a tubular gadolinium marker. The sagittal images were reformatted to obtain a series of axial images along the axis of the marker tube to facilitate identification of the marker axial centers.




Figure 3: Example of two binary reformatted MR images axial to a fiducial marker. The segmentation algorithm finds the best fitting circle center indicated by a big cross on both images. The algorithm is able to find the center, even when air bubbles in the marker on the left contaminate the image. Small crosses indicate the border of the detected marker.

3 Results

Two clinical procedures have been performed on a 3T Philips Intera MRI scanner (Philips Medical Systems, Best, NL). One procedure encompassed combined biopsy and gold marker placements, the second employed biopsy only.

Figure 4 shows the results of the combined procedure. Four targets were selected on axial T2 weighted FSE images (Figure 4, top row). The targets were placed at hypo-intense regions on the T2 weighted images, which represent suspicious areas for prostate cancer. One biopsy was procured from each of three target sites, while one target was biopsied twice. A gold marker was implanted at each target location after biopsy of the site.

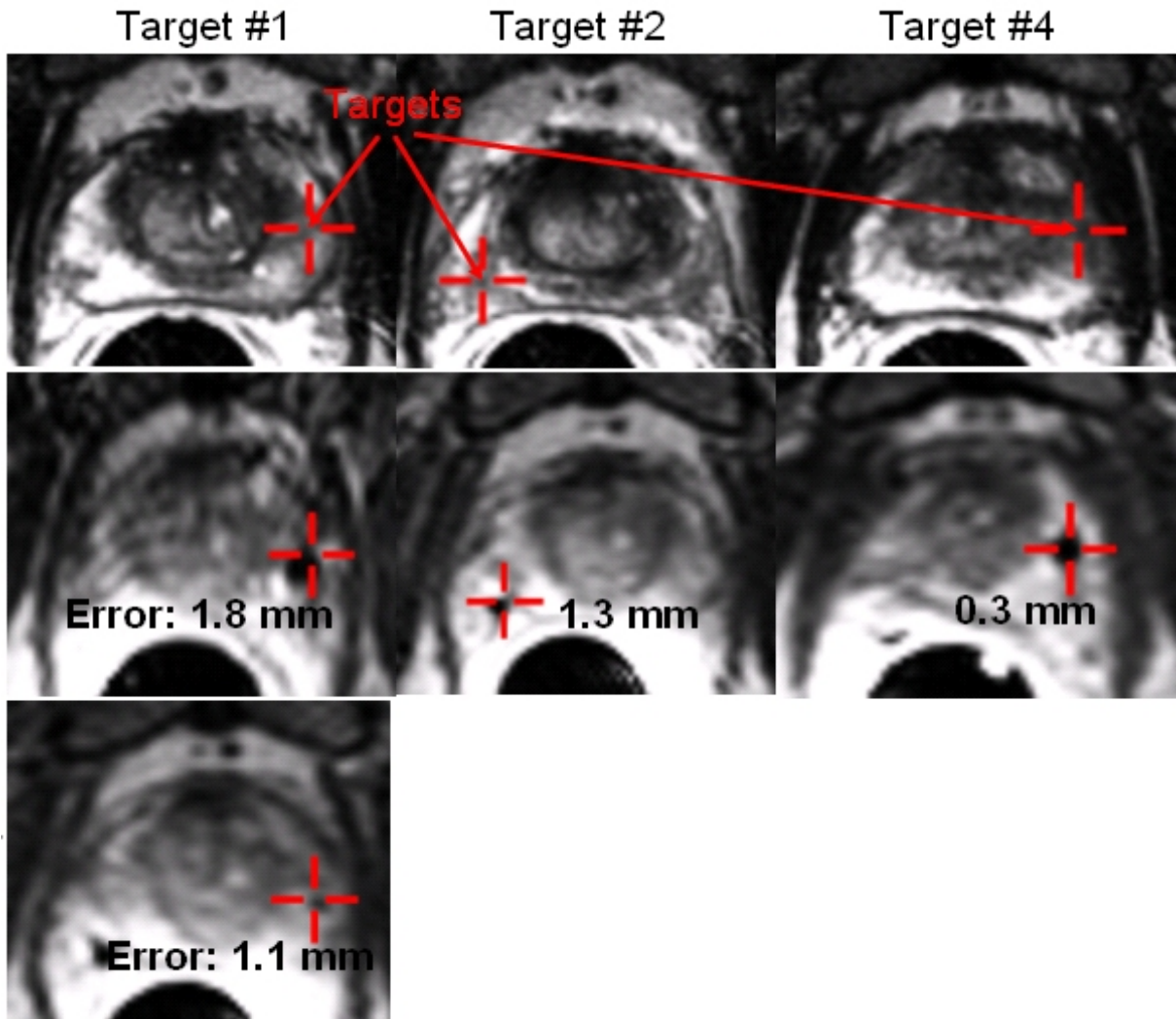


Figure 4: Targeting images, needle visualization images, and gold marker image of clinical procedure using the transrectal prostate intervention system. Top image row: Suspicious targets (red cross hairs) were selected on axial TSE T2-weighted images. Second image row: The needle tip void was visualized in axial TSE proton density images. The desired targets match the actual position of the needle. Error number: The number indicates the in-plane targeting error for the needle placement. Third image row: Axial TSE proton density image showing the location of the marker placed at target location number 1. The marker void is visible close to the target.

The targeting accuracy of three biopsy needle placements was assessed using proton weighted axial TSE needle confirmation images (Figure 4, second row). The void created by the susceptibility artifact of the biopsy needle is visible close to the target. The mean in-plane targeting error for the biopsies was 1.1 mm with a maximum error of 1.8 mm. No needle confirmation image was taken from target number 3. The gold marker location for target number

1 was confirmed on subsequent needle confirmation images (Figure 4, third row). The distance from the center of the marker to the target location was 1.1 mm.

The pathology report revealed that the biopsy sample taken at target number 1, was positive for prostate cancer with a Gleason grade of 3+4. The patient was subsequently treated with external radiation beam therapy. The implanted gold markers were used to adjust for daily set-up changes to optimize the radiation therapy.

The average procedure time was 75 minutes.

4 Conclusion

We reported the results of initial clinical procedures to evaluate the feasibility of performing prostate interventions with the proposed system. The clinical procedures demonstrated accurate and fast needle targeting of the complete clinical target volume. The errors and procedure time compare favorably to reported results (average error 1.8 mm and average procedure times of 76 minutes) achieved with our previously reported active tracking method in clinical trials [1,2]. The hybrid tracking method allows this system to be used on any MRI scanner without extensive systems integration and calibration.

References:

- [1] Krieger A. *Trans on Biomed Eng*, 52(2):306-313, 2005.
- [2] Susil RC, *J Urol*, 175(1):113-20, 2006.
- [3] Beyersdorff D. *Radiology*, 234(2):576-581, 2005.
- [4] Yu KK. *Radiol Clin North Am* 2000;38:59.

Author list:

Z. T. H. Tse¹, H. Elhawary¹, M. Rea¹, A. Zivanovic¹, B. L. Davies¹, M. Paley², G. Bydder³, I. Young¹
and M. Lamperth¹

¹Mechanical Engineering Department, Imperial College London, South Kensington Campus, SW7 2AZ,
London, UK

²Academic Radiology, Sheffield University, Sheffield, UK, ³Radiology Department, UCSD, San Diego, USA

Corresponding email: t.tse06@imperial.ac.uk

Phone no. : 44 20 7589 5111 Ext 57068

Specific topic: Robotics

Presentation: Oral